



David J. Clark, DDS

# An Improved Quadrant Class II Composite Technique

When a quadrant of Class II composite resin restorations shows up on our schedule, do we look forward to that work, or do we feel a small sense of dread? When I adopted the use of a dental microscope 20 years ago in my practice, most of the procedures got better, and eventually some got faster. However, until recently, I was never thrilled with either the clinical outcome or the amount of time spent on doing quadrant Class II composites. In this article, we will examine a modern approach with nonretentive saucer preparations, matrixing, and injection molding with a balance of bulk flowable and regular paste strategies. Today, the process can truly be better, faster, and more enjoyable.

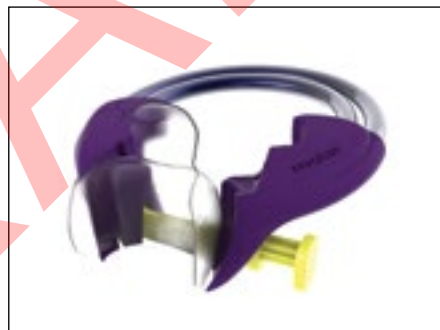In a previous article, “The Seven Deadly Sins of Traditional Class II Restorations” (*Dentistry Today*, January 2017), I listed several “sins” of posterior composites. Two of the sins

were burnished metal matrices and weak/worn out separators (Figure 1). There is a legacy problem with the way we think about posterior composite. Traditional wedges, matrices, separators, and boxy cavity preparations never gave us the freedom to create the forces needed to separate the teeth aggressively, and the resultant contours of the restorations were badly compromised by the shape and the flimsiness of thin sectional metal matrices. We have found that the bigger the wedge, the flatter the filling, the smaller the contact; and when we did back-to-back restorations, the problems compounded. That brings us to one of the most common questions that comes up, in fact at almost every one of my lectures—how to best do *back-to-back* posterior composites? Until now, we have had the following 2 choices:

*continued on page*



**Figure 1.** Comparison of the Trident separator (left side, green) and the Bioclear Twin Ring (right side, purple) 25 times to 16 mm opening. The green separator has lost nearly half of its power. Worn out or weak separators disallow a consistently healthy, strong contact for a host of reasons.



**Figure 2.** The Biofit HD matrix is shown with the Molar Twin Ring separator and a Large Diamond Wedge.



**Figure 3.** Top view of the Diamond Wedges S, M, L, XL, and DC/F (deep caries/fluting) (patent and patent pending). The diamond cutout allows it to pass through the narrow part of the embrasure and then spring open to stay locked in place and apply pressure evenly to avoid line angle overhangs.



**Figure 4.** Oblique view of the Diamond Wedges shows the low profile needed to allow broad contacts. Note that as the wedges get larger, they do not get taller. This allows the aggressive emergence profile of the Biofit Matrix to be maintained.



**Figure 5.** Yellow (bicuspid) and purple (molar) Twin Ring separators show the advanced design that allows better adaptation to the teeth, and advanced spring design that will resist spring fatigue.



## An Improved Quadrant Class II...

continued from page xx

*Option 1* was to matrix and fill all the teeth in the quadrant at the same time, risking open contacts because so much space was left over after the matrices were removed. Open contacts are unacceptable in patient terms (chronic food impaction, pain, and disruption in quality of life) and in dental health terms (recurrent decay and periodontal breakdown).

*Option 2* was to place a matrix and fill one tooth at a time. Option 2 takes a lot longer, and there is always the risk that one tooth will end up wider than it should and the neighbor too narrow. There is stressful disassembly and reassembly of the wedges and separators, bleeding; then disk grinding or burring of a tooth that seemed too wide (invaded the space of the neighboring tooth) or had the wrong shape, more bleeding; and then reassembly of the matrix, wedge, and separator. Many times, we ended up with teeth that were too wide and too narrow despite our best efforts.

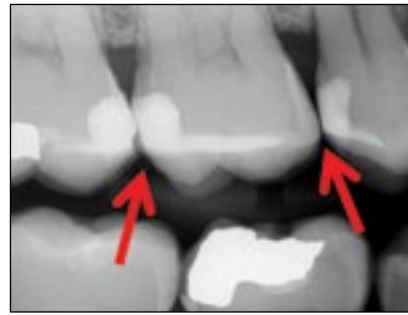In the case presented here, I incorporated a new strategy and excellent *third option*. The sequence, which requires the Biofit Matrix System (Bioclear), has the advantages of both old placement options *without* the disadvantages. This is possible because of the strength and the anatomic shape of the new Biofit HD matrix when accompanied by the Diamond Wedge, Twin Ring, and HeatSync composite heater (components of the Bioclear system) (Figures 2 to 6). The Twin Nitinol wires of the Twin Ring (*patent pending*) allow strong force to be distributed evenly on the rings, so the Twin Ring separator will not stretch out and lose power and like most traditional separators.

### CASE REPORT

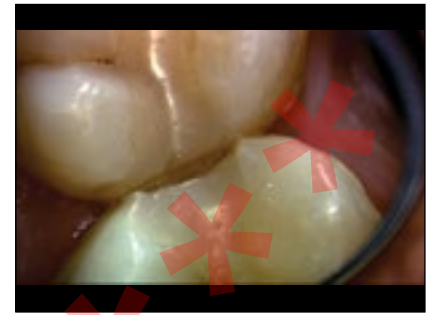The patient presented with Class II resin composite restorations placed previously by another dentist. The restorations were already chipped, broken, leaking, and undergoing recurrent decay. The patient reported that the marginal ridges began chipping soon after placement, resulting in food impaction. Tragically, they were placed only 4 years previously. Realistically, one must consider how many times a tooth can be restored and re-restored. With people living longer these days, these temporary



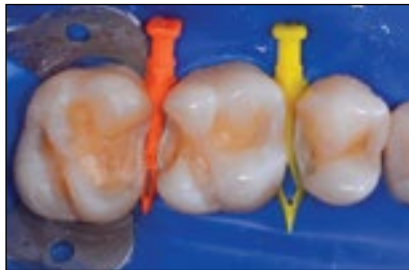
**Figure 6.** Bioclear HeatSync composite heater (as shown, allows injection molding with less voids and better marginal seal than cold composites). Both the flowable and the regular paste composite are heated to 155°F.



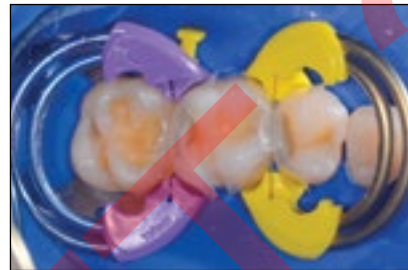
**Figure 7.** Pre-op bite-wing of the featured case showing chipped marginal ridge resultant from a sharp occlusal embrasure (left arrow) left by a traditional metal sectional matrix and the result of a burnished matrix and (right arrow) a slightly open contact.



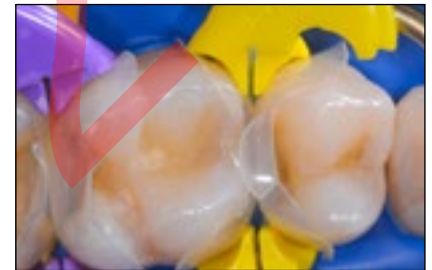**Figure 8.** Preoperative view shot through the lens of a Global microscope of the chipped marginal ridge in Figure 7 radiograph, an all too common sight with traditional Class II composites.



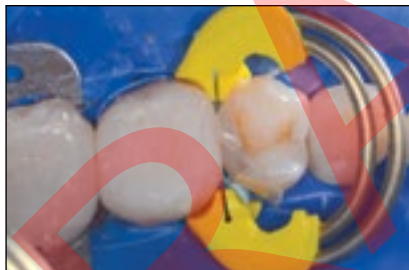**Figure 9.** Modern cala lily and saucer preparations after removal of chipping, leaking, and recurrent caries affected restorations. Pre-wedging, a critically important step, is demonstrated, with medium and Large Diamond wedges.



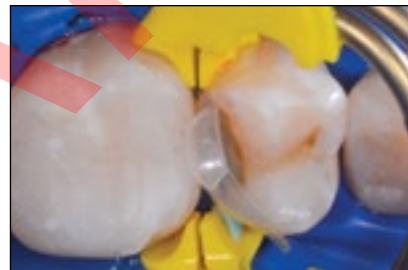**Figure 10.** The first step matrixing and wedging all the teeth together is shown. The first molar will be filled first.



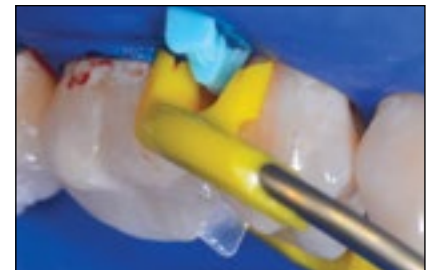**Figure 11.** High-magnification image of the extensive occlusal embrasure containment of the Biofit HD matrices. This important advancement in matrix technology creates better injection pressure, less need for hand manipulation of the composite, and a drastic reduction of dangerous and time-consuming occlusal embrasure grinding.



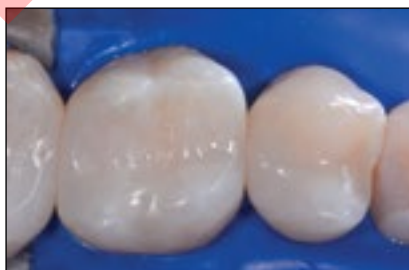**Figure 12.** When the first molar, then the second molar have been filled, the bicuspid can be injection molded once the other matrices on the other teeth have been removed and the final Twin Ring separator removed and replaced. There is usually no need to remove the wedge when one of the back-to-back restorations is finished and corresponding matrices removed. This saves valuable time, also eliminating bleeding problems.



**Figure 13.** High-magnification of Figure 12 demonstrates a modern cavity preparation with infinity edge margins. Note that the separator can be placed on the distal side of the wedge instead the normal straddling position. Either is acceptable with the flexibility of the Diamond Wedges.



**Figure 14.** Buccal view of the Bicuspid Twin Ring (yellow) straddling the Extra-Large Diamond wedge (blue). When possible, the operator can leverage the technique of progressive wedging. *Progressive wedging* is the use of progressively larger wedges moving from the pre-wedging stage to final wedging.



**Figure 15.** Final postoperative view of monolithic injection molded Class II composite resin (3M Filtek Posterior Bulk Fill, shade A1, regular and flowable resins together) restorations.

tooth-colored fillings are an embarrassment and a disservice. We must and can do better!

A clinical video shot through the lens of a Global Microscope documented the preoperative conditions and filling technique and is posted in *Dentistry Today's* online library ([dentistrytoday.com/link](http://dentistrytoday.com/link)).

The pre-op microphotograph and radiograph (Figures 7 and 8) demonstrated chipping marginal ridges, common to restorations placed with traditional metal sectional matrices that have left sharp marginal ridges.

The pre-op radiograph and high magnification image demonstrate the sum of the previous placement errors, a sharp, "kissy" contact that eventually chipped leading to food impaction and next to it a slightly open contact. Both were causing food impaction. Most of today's microfill and nanofill composite resins have excellent compressive strength but relatively weak diametral tensile strength. What does that mean to you, as the clinician? *Do not leave sharp corners!* The problem is, with burnished metal matrices that

continued on page



### An Improved Quadrant Class II...

continued from page xx

are coaxed laterally to gain a contact, the contact ends up being too far to the occlusal and unsupported gingivally.

#### Steps for Ideal Quadrant Class II Composites

**Step 1**—Place rubber dam, apply disclosing solution, and blast with aluminum trihydroxide.

**Step 2**—Prewedge, then cut modern cavity preparations (Figure 9). (Visit the Bioclear Learning Center for more information.)

**Step 3**—Place Biofit matrices on all teeth (I prefer the stiffer HD variety) (Figures 10 and 11), Diamond Wedges, and appropriate Twin Ring Separators.

**Step 4**—Restore the “middle” tooth (Figure 12), and then remove the separators and then the matrices from the middle tooth. The wedges and the other matrices will usually not need to be disassembled or reassembled (Figure 13).

**Step 5**—Replace the separators and restore the distal tooth. Remove the wedge, matrix, and separator from the distal tooth.

**Step 6**—Restore the mesial tooth/teeth. A facial view of the coordinated fit of the blue extra-large Diamond Wedge and yellow Twin Ring are pictured in Figure 14.

#### CLOSING COMMENTS

This technique allows for ideal landmark preservation. The final contours of the restorations should match the blueprint that is demonstrated by the very anatomic matrices. Because the Biofit matrices are removed so easily, it is often not necessary to remove and then replace the wedge, thus saving time and potential bleeding. No contouring of the interproximal is necessary, and this is a huge advantage. Because the restorations were relatively shallow occlusogingivally (4.0 mm) and the matrices allow light transmission, there was no need to do any layering. Layering decreases our clinical procedural efficiency. Furthermore, and more importantly, multiple studies have shown that *layered restorations are more prone to gaps and voids*. We clinicians have battled these cases for decades, working too hard for oftentimes mixed results. The immediate postoperative photo (Figure 15) demonstrates the look of injection-molded monolithic restorations with rounded occlusal embrasures. Den-

tists and ceramists alike often remark that Injection Molded Bioclear restorations look more like porcelain restorations than they do composite resin restorations. The excellent integrity of this style of the modern composite resin restoration is being demonstrated in 7-year follow-up studies.♦

**Dr. Clark** maintains a private practice in Tacoma, Wash, and is the founder of the Academy of Microscope Enhanced Dentistry. He is also a course director at the Newport Coast Oral Facial Institute and the director of the Bioclear Learning Center in Tacoma. He is on the editorial board for several journals and has lectured internationally. He served for 18 months as the lecturer for Clinicians Report (formerly CRA) and served on its board of directors for several years. His main areas of interest include the redesigning of restorative and endodontic access preparations. He can be reached at [drclark@microscopedentistry.com](mailto:drclark@microscopedentistry.com).

*Disclosure: Dr. Clark is the owner of Bioclear Matrix Systems. Please sign and return forms. Thank you!*

continued on page